

■ ASPECTS OF CURRENT MANAGEMENT

The prophylaxis and treatment of heterotopic ossification following lower limb arthroplasty

T. N. Board,
A. Karva,
R. E. Board,
A. K. Gambhir,
M. L. Porter

From Wrightington Hospital, Wigan and the University of Manchester, Manchester, England

Heterotopic ossification following joint replacement in the lower limb occurs in 3% to 90% of cases. Higher grades of heterotopic ossification can result in significant limitation of function and can negate the benefits of joint replacement. The understanding of the pathophysiology of this condition has improved in recent years. It would appear to be related to a combination of systemic and local factors, including over-expression of bone morphogenetic protein-4. There is currently little evidence to support the routine use of prophylaxis for heterotopic ossification in arthroplasty patients, but prophylaxis is recommended by some for high-risk patients. Radiotherapy given as one dose of 7 Gy to 8 Gy, either pre-operatively (< four hours before) or post-operatively (within 72 hours of surgery), appears to be more effective than indometacin therapy (75 mg daily for six weeks). In cases of prophylaxis against recurrent heterotopic ossification following excision, recent work has suggested that a combination of radiotherapy and indometacin is effective. Advances in our understanding of this condition may permit the development of newer, safer treatment modalities.

Heterotopic ossification (HO) is the abnormal formation of mature lamellar bone in soft tissues. It was first described in 1883 by Reidel, a German physician.¹ The condition has since acquired many names, including paraosteoarthropathy, myositis ossificans, periarticular new bone formation, periarticular ectopic ossification, neurogenic osteoma, neurogenic ossifying fibromyopathy and heterotopic calcification.² Heterotopic ossification is a clear and accurate descriptive term which is now used throughout the literature.

Although HO can occur after local or neurological trauma and as a result of genetic disorders, this review describes our current understanding of the disease and the methods of prophylaxis and treatment when it occurs following the soft-tissue trauma related to joint replacement in the lower limb.

Clinical presentation

Heterotopic ossification following primary replacement of the hip or knee is typically asymptomatic and is most commonly identified as an incidental radiological finding. When symptomatic, it presents with a reduced range of movement and may lead to a poor outcome following replacement. Pain is uncommon, but can occur. Soft-tissue signs are uncommon around the hip owing to the signif-

icant soft-tissue cover, but localised warmth, mild oedema and erythema may occur, masquerading as signs of infection.³ HO can be detected on a bone scan as early as three weeks after operation, with increased uptake in the soft tissues surrounding the hip. Plain radiographs will not reveal any abnormality for four to six weeks.³ The increased bone turnover that occurs in HO can be detected as early as one week after surgery, with excessive rises in the specific osteoclastic and osteoblastic markers (CTX-1 and P1NP) detected in venous blood.⁴ Extensive bone formation may occur within three months but full maturation of bone takes up to one year.⁵

Classification

HO is most commonly classified using the Brooker system⁶ (Fig. 1). This is based on the appearance of ossification on a plain antero-posterior radiograph of the hip (Figs 2 and 3):

Grade 1: Islands of bone lie within the soft tissues about the hip.

Grade 2: Bony spurs protrude from either the femur or the pelvis, with a gap of more than 1 cm between opposing bony ends.

Grade 3: The gaps between the spurs are less than 1 cm.

Grade 4: Apparent ankylosis of the hip due to the heterotopic ossification.

■ T. N. Board, MRCS, MSc, FRCS(Orth), Lecturer in Orthopaedics, Specialist Registrar

■ A. Karva, MBBS, MRCS, MS(Orth), Clinical Fellow in Orthopaedics

■ A. K. Gambhir, MBChB, FRCS(Orth), Consultant Orthopaedic Surgeon

■ M. L. Porter, MBChB, FRCS(Ed), FRCS(Orth), Consultant Orthopaedic Surgeon

Wrightington Hospital for Joint Diseases, Appley Bridge, Wigan WN6 9EP, UK.

■ R. E. Board, MBChB, MSc, MRCP, Specialist Registrar in Medical Oncology
Christie Hospital, Wilmslow Road, Manchester M20 4BX, UK.

Correspondence should be sent to Mr T. N. Board;
e-mail: tim@timboard.co.uk

©2007 British Editorial Society of Bone and Joint Surgery
doi:10.1302/0301-620X.89B4.18845 \$2.00

J Bone Joint Surg [Br]
2007;89-B:434-40.

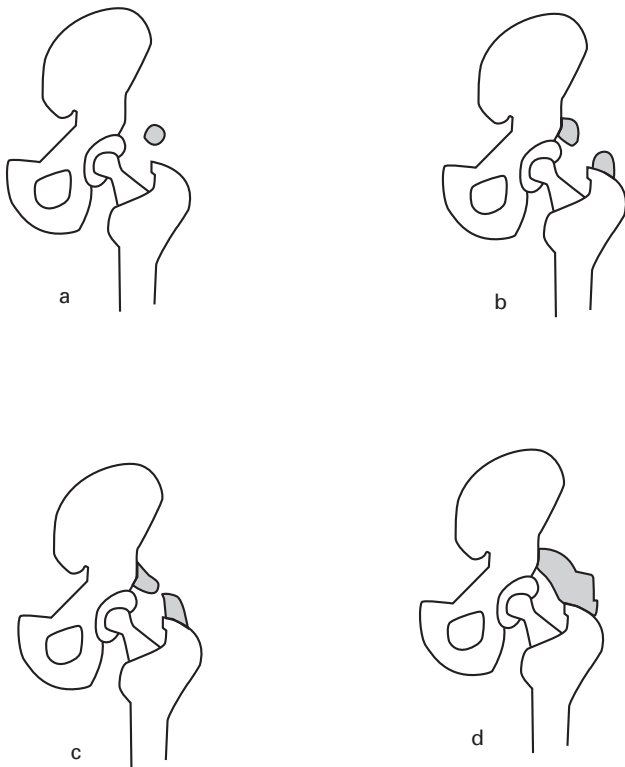


Fig. 1

Brooker classification showing a) grade 1: islands of bone within the soft tissues about the hip, b) grade 2: bony spurs from either the femur or the pelvis, with a gap of more than 1 cm between opposing bony ends, c) grade 3: the gaps between the spurs are less than 1 cm and d) grade 4: apparent ankylosis of the hip due to the heterotopic ossification.

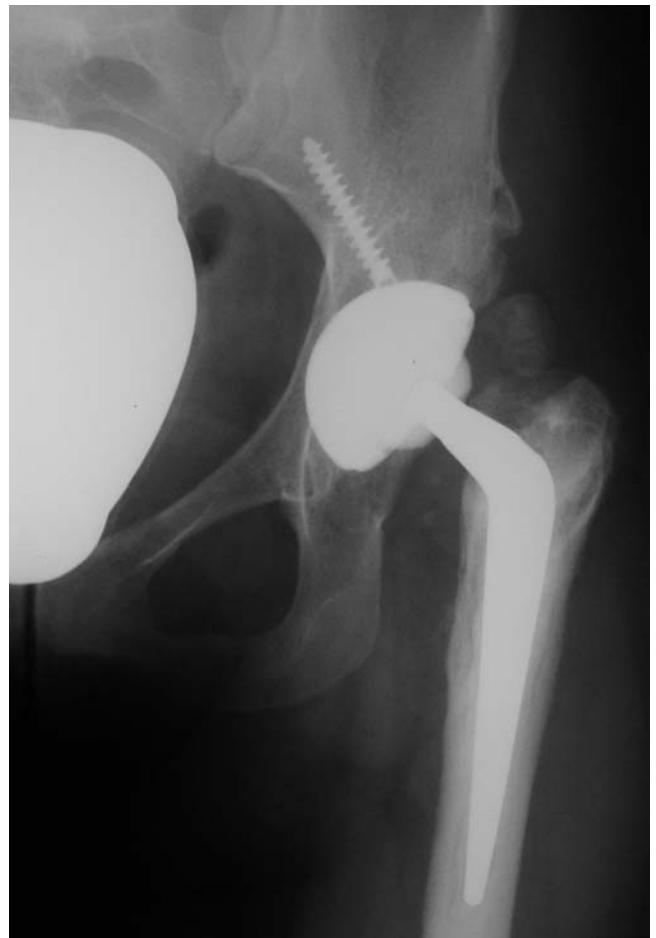

Fig. 2

Radiograph showing islands of heterotopic ossification around a hybrid total hip replacement (Brooker grade 1).

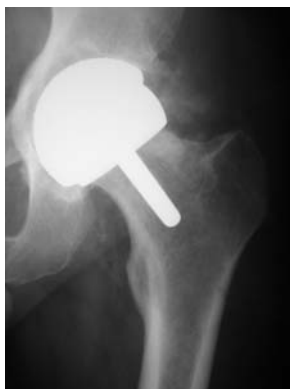

Fig. 3a

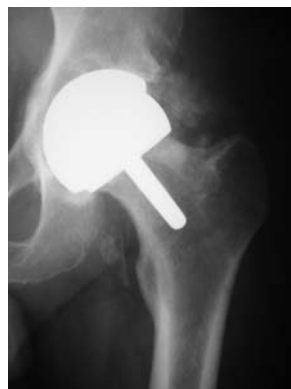

Fig. 3b

Radiograph showing the development of heterotopic ossification following resurfacing arthroplasty a) at two months (grade 2) and b) at 4 months (grade 3).

It has been shown that presence of grade 1 or 2 HO does not influence the outcome of total hip replacement (THR) whereas grades 3 and 4 are associated with a less favourable outcome.⁷ Schmidt and Hackenbroch⁸ suggested an

alternative, more complex grading system, although this is little used and will not be described here.

Aetiology and pathophysiology

The aetiology of HO can be broadly divided into traumatic, neurological and genetic, with that following arthroplasty falling into the traumatic group. The abductor compartment is most commonly involved.⁵

The osteoblastic cell responsible for HO is believed to result from inappropriate differentiation of pluripotent mesenchymal stem cells.¹ The definitive causal factor for this is not yet clear, but it seems likely that there is an interplay between local and systemic factors. Overexpression of bone morphogenetic protein-4 (BMP-4) has been shown to occur in fibrous dysplasia ossificans progressiva,⁹ a genetic form of HO, and inhibition of BMP-4 by Noggin (a BMP antagonist) has recently been shown to prevent HO in three separate experimental models.¹⁰ Prostaglandin-E₂ has been proposed as one responsible systemic factor, a hypothesis underpinned by the observation that inhibitors of prostaglandins, particularly indometacin, significantly reduce the incidence of HO.¹¹

Table I. Summary of the recorded incidence of heterotopic ossification following total knee replacement (TKR)

Study	Procedure	Number of patients	Incidence (%)
Daulry and Jiranek ¹⁸	TKR	75/500	15
Toyoda et al ²⁰	TKR	25/63	39
Hasegawa et al ²¹	TKR	10/221	5
Rader et al ²²	TKR	54/615	9
Furia and Pellegrini ²³	TKR	25/98	26
Barrack et al ²⁴	Revision TKR	75/135	56

Incidence and risk factors

Following THR the incidence of HO has been recorded to be between 5% and 90%.^{6,12-16} However, the incidence of clinically significant HO (grade III/IV) varies from 3% to 7%.^{14,17} The incidence following total knee replacement (TKR) is somewhat lower. One of the largest series in the literature followed up 500 consecutive patients with TKR and found an incidence of 15% of all grades,¹⁸ but of those only 1% (four patients) were symptomatic. The authors also noted that the degree of pre-operative deformity appeared to be related to the severity of HO. Other studies have described incidences ranging from 3.8% to 39% in primary TKR,¹⁹⁻²³ and 56% in revision TKR²⁴ (Table I).

Risk factors for HO around the hip include male gender,²⁵ old age, a history of HO in the ipsilateral or contralateral hip,¹⁵ a pre-existing hip fusion, hypertrophic osteoarthritis,^{15,16} ankylosing spondylitis,^{5,26} diffuse idiopathic skeletal hyperostosis,²⁷ Paget's disease, post-traumatic arthritis, osteonecrosis, and rheumatoid arthritis. Patients with a previous history of HO in an ipsilateral joint are at greater risk of developing HO than those in whom previous HO was on the contralateral side.²⁸

Risk factors that are related to surgical technique and which are potentially modifiable include the extent of soft-tissue dissection, bone trauma, persistence of bone debris (reamings, marrow or dust within the surgical field) and the presence of a haematoma. Whether the surgical approach influences the incidence of HO is debatable. Morrey, Adams and Cabanela²⁹ showed no significant difference in the rate of HO between the anterolateral, transtrochanteric and posterior approaches, and Purtill et al³⁰ supported this view showing no significant difference between the anterolateral and transtrochanteric approaches. However, Ashton et al²⁸ found that the posterior approach was associated with a lower rate of HO than the anterolateral or transtrochanteric approaches. Similarly, there is no convincing evidence to suggest that uncemented or cemented implants have a higher level of ossification.³¹⁻³⁴ Intra-operative release of the psoas tendon is known to be associated with HO formation in this region.³⁵

Treatment of symptomatic HO

Patients who develop clinically significant HO may suffer severe limitation of mobility owing to joint stiffness. Treatment may be conservative or operative. Conservative management includes intensive physiotherapy during the

maturation phase of the disease in an attempt to limit the final stiffness. We are not aware of any data regarding the effectiveness of this treatment. There is no role for non-steroidal anti-inflammatory drugs (NSAIDs) or radiotherapy as a treatment for pre-existing HO. Surgical treatment involves excision of the heterotopic bone and can be expected to improve the functional outcome. One study described excision of HO in 53 patients following THR, with an increase in all movements (mean values: flexion 34°, abduction 22° and rotation 21°).³⁶ There is little information concerning excision of HO causing symptoms following knee replacement.³⁷ Our current practice is to postpone surgical excision until maturation of the ossification, typically at 12 to 24 weeks. Our technique for excision uses a safety-first approach. Adequate exposure is paramount and identification of the neurovascular structures is mandatory. In particular, the sciatic nerve should be isolated and protected throughout dissection of the ossification about the hip. Ectopic bone should be removed from surrounding soft tissues with sharp dissection, staying on bone wherever possible. The plane between HO and true cortex can easily be defined by gentle excavation of the ossification with an osteotome, when the true cortex will be revealed as a denser, tougher layer of bone. This plane can then be used to lift off the ossified layer from the femur. Some form of prophylaxis against HO should be used in these patients, and the methods available are discussed below.

Prophylaxis against HO formation

Patients with a high risk of developing HO are often given prophylactic treatment following primary or revision arthroplasty. All patients undergoing excision of symptomatic HO should also receive some form of prophylaxis. The two main treatments available are radiation therapy and NSAIDs. Bisphosphonates have been used in the past, but their use has been discontinued as they only postpone ossification until treatment is stopped.³⁸

Prophylaxis with NSAIDs. NSAIDs act by inhibiting the production of prostaglandins, particularly prostaglandin-E₂. Potential side effects include gastrointestinal bleeding, renal impairment and exacerbation of asthma. The risk of bleeding may be further increased in patients on warfarin, owing to the antiplatelet effects of NSAIDs and interaction between the two drugs, but there is disagreement in the lit-

erature and some studies suggest that concomitant treatment is safe.³⁹

The use of NSAIDs to prevent the formation of HO following hip replacement has been the subject of a Cochrane Review.⁴⁰ A total of 16 randomised trials totalling nearly 5000 patients were included. Peri-operative NSAIDs were seen to reduce the incidence of HO by between one-half and two-thirds. However, there was a lack of data concerning any long-term benefits, such as pain control and mobility, and some patients receiving NSAIDs experienced gastrointestinal side effects.

The efficacy of indometacin in preventing HO has been demonstrated in many studies.^{11,41-44} The most common treatment is to give 25 mg three times a day for five to six weeks. This treatment is attractive because of its simplicity and low cost. Indometacin has been shown to increase the rate of nonunion in fractures of long bones.⁴⁵ This may be of concern when the operation is performed through a trochanteric osteotomy or when uncemented components are used as both these techniques rely on bony union for success.

The HIPAID (safety and efficacy of routine post-operative ibuprofen for pain and disability related to ectopic bone formation after hip replacement surgery) study randomised patients to receive a placebo or ibuprofen 1200 mg daily following elective primary or revision hip replacement.⁴⁶ There was a significant decrease in the risk of developing HO of any grade (relative risk 0.69) and in the risk of developing Brooker grade 3 or 4 HO (relative risk 0.44) in those receiving ibuprofen. However, this did not translate into any meaningful change in clinical outcome, as there was no significant difference in pain in the hip or physical function between the two groups. Furthermore, there was an increased risk of major bleeding complications in the ibuprofen group (risk ratio 2.09, $p = 0.046$).⁴⁶

Prophylaxis with radiotherapy. Several studies have shown the efficacy of radiation therapy in reducing the incidence of HO following lower limb replacement. The most appropriate dose regimen appears to be 7 Gy to 8 Gy given as a single fraction either < four hours pre-operatively or < 72 hours post-operatively.⁴⁷⁻⁴⁹

Rationale for radiotherapy. The observation that ionising radiation could halt fracture healing was first made in a rat model, where a dose of 30 Gy given within one week of fracture was shown to prevent union.⁵⁰ The importance of timing was further reinforced with the demonstration that giving radiotherapy in the second week following implantation of demineralised bone matrix in a rat model resulted in the same degree of bone formation as in controls, whereas bone formation was significantly reduced in subjects receiving radiotherapy within the first week.⁵¹ The mechanism of action was thought to be due to inhibition of the fast-dividing osteoprogenitor cells that are present within the first week and which then differentiate into mature cell types such as osteoblasts. The lower mitotic rate

of mature cells protects them from the damage to DNA caused by radiation.

Radiotherapy regimen. The first study describing the use of radiation therapy to prevent HO following hip replacement in high-risk patients employed a total dose of 20 Gy in fractions (ten separate doses totalling 20 Gy).⁵² Once the effectiveness of radiation therapy had been established, subsequent investigations examined the possibility of reducing the dose used. In a retrospective series⁵³ a dose of 10 Gy in five fractions was found to be as effective as 20 Gy in ten fractions. The role of fractionated radiation therapy *versus* single-dose therapy was investigated in two independent studies.^{47,48} Both concluded that a single dose of 7 Gy to 8 Gy was as effective as fractionated therapy. Further reductions in dose may be less effective. A retrospective analysis of 107 hips given either 5.5 Gy or 7 Gy in a single dose showed that two patients receiving 7 Gy developed clinically significant HO (Brooker 3 or 4), whereas four in the 5.5 Gy group developed this level of HO.⁵⁴ The authors concluded that 5.5 Gy is not sufficient for prophylaxis. A prospective randomised trial investigated the difference in the rate of HO after prophylaxis with either 5 Gy in two fractions or 10 Gy in five fractions. Of 19 patients receiving 5 Gy, two developed clinically significant HO, compared to one of 30 receiving 10 Gy.³⁸ The authors concluded that there was no significant difference between the two groups, but acknowledged that a true difference may not have been observed owing to the small sample size. It seems that a dose of 7 Gy to 8 Gy given in a single dose is both efficacious and convenient for patients undergoing replacement.

The timing of prophylaxis with radiotherapy has also been investigated. One randomised controlled trial compared a single dose of 7 Gy given less than four hours before operation with 17.5 Gy (five fractions) given within 72 hours of surgery.⁵⁵ The authors found a statistically significant difference in favour of post-operative therapy, although the disparity in dose between the two groups clouded this conclusion. A second randomised trial comparing 7 Gy to 8 Gy given in one dose either less than four hours before surgery or within 72 hours afterwards showed no significant difference in the rate of HO between the two groups.⁴⁹

In patients receiving uncemented implants consideration should be given to shielding the prosthesis when radiotherapy is given after operation. As the prosthesis relies on bony ingrowth for long-term fixation, there is a potential for radiation therapy to adversely affect the long-term survival of the implant. Although no clinical data exist to support this hypothesis, an animal study showed that at two weeks the pull-out strength of porous-coated rods inserted into rabbit tibiae was significantly reduced in those cases that had been treated with 10 Gy of post-operative radiation therapy. This difference was not observed at three weeks following the radiation therapy.⁵⁶ Shielding of the prosthesis raises concerns regarding the reduction of efficacy of the prophylaxis. One study retrospectively reviewed

Table II. The rates of heterotopic ossification of all Brooker grades and of Brooker grades 3 and 4 in randomised trials comparing radiotherapy and indometacin (percentage)

Study	All Brooker grades		Brooker 3 and 4	
	Radiotherapy	NSAID*	Radiotherapy	NSAID
Bremen-Kuhne et al ⁷¹	9/19 (47)	11/31 (36)	0/19 (0)	1/31 (3)
Kneller et al ⁶⁸	5/101 (5)	46/183 (25)	0/101 (0)	6/183 (3)
Kolbl et al ⁶⁷	39/188 (20)	18/113 (16)	1/188 (0.5)	2/113 (1.8)
Kolbl et al ⁶⁹	22/46 (48)	6/54 (11)	1/46 (2)	0/54 (0)
Sell et al ⁷⁰	2/77 (3)	18/77 (23)	0/77 (0)	0/77 (0)
Kienapfel et al ⁷²	12/49 (25)	20/55 (36)	0/49 (0)	0/55 (0)

* NSAID, non-steroidal anti-inflammatory drug

the rate of HO in 'at-risk' patients who received 15 Gy within 48 hours of surgery. The prostheses were shielded using Cerrobend blocks (Cerro Metal Products, Bellefonte, Pennsylvania). Only two of 18 patients developed HO (Brooker 1).⁵⁷ Although the authors concluded that shielding does not impair the efficacy of radiation therapy, the dose used was relatively high and the same may not be true for lower doses. When cemented implants are used there is no need to shield the implant, as secure long-term fixation is achieved intra-operatively.

Complications of prophylaxis with radiotherapy. The use of radiation therapy raises concerns about complications. There have been no documented cases of radiation-induced tumours following the use of radiotherapy for HO prophylaxis, and it has been recorded that no radiation-induced tumours occurred in patients receiving less than 30 Gy radiation therapy in a 50-year review of radiation-induced sarcomas.⁵⁸ The radiation dose to the testes is also of concern. One study evaluated the dose received at this site when prophylaxis was given with 8 Gy. Without a testicular shield the dose received was 0.25 Gy; with a shield the dose was reduced to 0.11 Gy.⁵⁹ Radiation-induced testicular damage is dose dependent. The testis is very radiosensitive and changes to spermatogenesis have been reported following as little as 0.2 Gy.⁶⁰ An account of patients who had received low-dose scattered irradiation during treatment of Hodgkin's disease showed that testicular doses of less than 0.2 Gy had no significant effect on follicle-stimulating hormone levels or sperm counts, but doses between 0.2 Gy and 0.7 Gy caused a transient dose-dependent increase in follicle-stimulating hormone and a reduction in sperm concentration, with a return to normal values within 12 to 24 months.⁶¹ It therefore seems likely that, with the use of a testicular shield, prophylaxis with radiotherapy is safe.

Radiotherapy is known to influence fracture healing⁵⁰ and therefore, when it is given following replacement of the hip performed via a trochanteric osteotomy, consideration should be given to shielding the osteotomy site. Trochanteric nonunion is reported to occur in 1.8% to 15% of cases,^{47,62} with the rate raising to 12% and 30% following radiation therapy.^{47,48,52} Few data exist regarding the potential reduction in efficacy of radiation therapy when the osteotomy site is shielded, although some shielding of

the gluteal muscles may occur if the whole trochanter is protected.

Comparison of radiotherapy and NSAIDs. Whereas the effectiveness of both radiation therapy and NSAIDs has been extensively studied, there is significant variability in the timing and duration of treatment, the daily dosage and the type of NSAID used.^{49,55,63-66} Several randomised controlled trials comparing NSAID and radiation therapy prophylaxis have been performed in THR.⁶⁷⁻⁷² These are summarised in Table II. A meta-analysis of randomised trials has recently been published.⁷³ Although two of the studies included acetabular fractures, the overall conclusions of the study were that radiation therapy was more efficient than NSAIDs at preventing Brooker grades 3 and 4 (risk ratio 0.42; 95% confidence interval (CI) 0.18 to 0.97) or any HO (risk ratio 0.75; 95% CI 0.37 to 1.71), the overall difference in absolute risk is, however, small.

Combination therapy. The combination of radiation therapy and NSAID as a prophylaxis was first suggested by Moed and Letournel⁷⁴ more than a decade ago. However, no further information was available on this subject until the publication of two recent retrospective studies.^{75,76} The first of these investigated the combination of 7 Gy post-operative radiation therapy and 75 mg indometacin for 15 days in patients with either hypertrophic osteoarthritis or previous HO formation undergoing THR. Of 54 patients followed up for one year, only one developed clinically significant HO.⁷⁵ The second study analysed the incidence of HO following operative treatment of acetabular fractures in 24 patients who received 7 Gy post-operative radiation therapy and 75 mg indometacin for six weeks.⁷⁶ One patient developed HO. The authors compared this with previous studies in the literature and concluded that the combination therapy was associated with the lowest rate of HO. No side effects secondary to the prophylaxis were reported in either study. Clearly, more powerful randomised trials are required to assess the merits of combined *versus* single therapy. However, the effects of treatment with differing modes of action might be expected to be enhanced. Such combined prophylaxis should be considered for those patients at highest risk of HO, namely those undergoing surgical excision of symptomatic HO with or without concomitant primary or revision arthroplasty.

Conclusion

Heterotopic ossification following replacement of joints in the lower limb is common but rarely results in significant symptoms. Based on current evidence, there is no indication to give prophylactic treatment following routine replacement. Primary prevention may be advocated for 'high-risk' patients, although the definition of 'high risk' varies. Prophylaxis with radiotherapy appears to be marginally more effective than medication with NSAIDs, although these are cheaper and easier to use after operation. Prophylaxis against recurrence should be used in those patients undergoing excision of symptomatic HO. There may be some justification for combining radiotherapy and NSAIDs in these patients. The understanding of the pathophysiology of HO has advanced in recent years and may allow the development of newer, safer methods of treatment in the future.

References

- Naraghi FF, DeCoster TA, Moneim MS, Miller RA, Rivero D. Heterotopic ossification. *Orthopedics* 1996;19:145-51.
- Sawyer JR, Myers MA, Rosier RN, Puzas JE. Heterotopic ossification: clinical and cellular aspects. *Calcif Tissue Int* 1991;49:208-15.
- Orzel JA, Rudd TG. Heterotopic bone formation: clinical, laboratory, and imaging correlation. *J Nucl Med* 1985;26:125-32.
- Wilkinson JM, Stockley I, Hamer AJ, Barrington NA, Eastell R. Biomechanical markers of bone turnover and development of heterotopic ossification after total hip arthroplasty. *J Orthop Res* 2003;21:529-34.
- Jowsey J, Coventry M, Robins PR. Heterotopic ossification: theoretical consideration possible etiological factors, and a clinical review of total hip arthroplasty patients exhibiting this phenomenon. In: *The hip: procs 5th Open Scientific Meeting of the Hip Society*. St Louis: CV Mosby, 1977:201-21.
- Brooker AF, Bowerman JW, Robinson RA, Riley LH Jr. Ectopic ossification following total hip replacement: incidence and a method of classification. *J Bone Joint Surg [Am]* 1973;55-A:1629-32.
- Pohl F, Seufert J, Tauscher A, et al. The influence of heterotopic ossification on functional status of hip joint following total hip arthroplasty. *Strahlenther Onkol* 2005;181:529-33.
- Schmidt J, Hackenbroch MH. A new classification for heterotopic ossifications in total hip arthroplasty considering the surgical approach. *Arch Orthop Trauma Surg* 1996;115:339-43.
- Shafritz AB, Shore EM, Gannon FH. Overexpression of an osteogenic morphogen in fibrodysplasia ossificans progressiva. *N Engl J Med* 1996;335:555-61.
- Hannallah D, Peng H, Young B, et al. Retroviral delivery of Noggin inhibits the formation of heterotopic ossification induced by BMP-4, demineralized bone matrix, and trauma in an animal model. *J Bone Joint Surg [Am]* 2004;86-A:80-91.
- Ahregart L, Lindgren U, Reinhold FP. Comparative study of the effects of radiation, indomethacin, prednisilone and ethane-1-hydroxy-1, 1-disphosphate (EHDP) in the prevention of ectopic bone formation. *Clin Orthop* 1988;229:265-73.
- Charnley J. The long-term results of low friction arthroplasty of the hip performed as a primary intervention. *J Bone Joint Surg [Br]* 1972;54-B:61-76.
- Rosendahl S, Christoffersen K, Norgaard M. Para-articular ossification following total hip replacement. *Acta Orthop* 1973;43:400-4.
- Harris WH. Clinical results using Muller-Charnley total hip prosthesis. *Clin Orthop* 1972;86:95-101.
- Ritter MA, Vaughan RB. Ectopic ossification after total hip arthroplasty: predisposing factors, frequency and effect on results. *J Bone Joint Surg [Am]* 1977;59-A:345-51.
- DeLee J, Ferrari A, Charnley J. Ectopic bone formation following low friction arthroplasty of the hip. *Clin Orthop* 1976;121:53-9.
- Chao ST, Lee SY, Borden LS, et al. External beam radiation helps prevent heterotopic bone formation in patients with a history of heterotopic ossification. *J Arthroplasty* 2006;21:731-6.
- Dalury DF, Jiranek WA. The incidence of heterotopic ossification after total knee arthroplasty. *J Arthroplasty* 2004;19:447-52.
- Harwin SF, Stein AJ, Stern RE, Kulick RG. Heterotopic ossification following primary total knee arthroplasty. *J Arthroplasty* 1993;8:113-16.
- Toyoda T, Matsumoto H, Tsuji T, Kinouchi J, Fujikawa K. Heterotopic ossification after total knee arthroplasty. *J Arthroplasty* 2003;18:1076.
- Hasegawa M, Ohashi T, Uchida A. Heterotopic ossification around distal femur after total knee arthroplasty. *Arch Orthop Trauma Surg* 2002;122:274-8.
- Rader CP, Barthel T, Haase M, Scheidler M, Eulert J. Heterotopic ossification after total knee arthroplasty: 54/615 cases after 1-6 years' follow-up. *Acta Orthop Scand* 1997;68:46-50.
- Furia JP, Pellegrini VD Jr. Heterotopic ossification following primary total knee arthroplasty. *J Arthroplasty* 1995;10:413-19.
- Barrack RL, Brumfield CS, Rorabeck CH, Cleland D, Myers L. Heterotopic ossification after revision total knee arthroplasty. *Clin Orthop* 2002;404:208-13.
- Ahregart L. Periarticular heterotopic ossification after total hip arthroplasty: risk factors and consequences. *Clin Orthop* 1991;263:49-58.
- Sundaram NA, Murphy JC. Heterotopic bone formation following total hip arthroplasty in ankylosing spondylitis. *Clin Orthop* 1986;207:223-6.
- Fahrer H, Koch P, Ballmer P,ENZLER P, Gerber N. Ectopic ossification following total hip arthroplasty: is diffuse idiopathic skeletal hyperostosis a risk factor? *Br J Rheumatol* 1988;27:187-90.
- Ashton AL, Bruce W, Goldberg J, Walsh W. Prevention of heterotopic bone formation in high risk patients post-total hip arthroplasty. *J Orthop Surg* 2000;8:53-7.
- Morrey BF, Adams RA, Cabanela ME. Comparison of heterotopic bone after anterolateral, transtrochanteric, and posterior approaches for total hip arthroplasty. *Clin Orthop* 1984;188:160-7.
- Purtill JJ, Eng K, Rothman RH, Hozack WJ. Heterotopic ossification: incidence in cemented versus cementless total hip arthroplasty. *J Arthroplasty* 1996;11:58-63.
- Gebuhr P, Sletgard J, Aisgard J, et al. Heterotopic ossification after hip arthroplasty: a randomized double-blind multicenter study tenoxicam in 147 hips. *Acta Orthop Scand* 1996;67:29-32.
- Maloney WJ, Krushell RJ, Jasty M, Harris WH. Incidence of heterotopic ossification after total hip replacement: effect of the type of fixation of the femoral component. *J Bone Joint Surg [Am]* 1991;73-A:191-3.
- Nollen JG, Van Douveren FO. Ectopic ossification in hip arthroplasty: a retrospective study of predisposing factors in 637 cases. *Acta Orthop Scand* 1993;64:185-7.
- Rockwood PR, Horne JG. Heterotopic ossification following uncemented total hip arthroplasty. *J Arthroplasty* 1990;5(Suppl):43-6.
- Velasco AD, Allan DB, Wroblewski BM. Psoas tenotomy and heterotopic ossification after Charnley low-friction arthroplasty. *Clin Orthop* 1993;291:193-5.
- Cobb TK, Berry DJ, Wallrichs SL, Ilstrup DM, Morrey BF. Functional outcome of excision of heterotopic ossification after total hip arthroplasty. *Clin Orthop* 1999;361:131-9.
- Freedman EL, Freedman DM. Heterotopic ossification following total knee arthroplasty requiring surgical excision. *Am J Orthop* 1996;25:559-61.
- Padgett DE, Holley KG, Cummings M, et al. The efficacy of 500 CentiGray radiation in the prevention of heterotopic ossification after total hip arthroplasty: a prospective, randomized, pilot study. *J Arthroplasty* 2003;18:677-86.
- Vesell ES. Failure of indomethacin and warfarin to interact in normal healthy volunteers. *J Clin Pharmacol* 1975;15:486-95.
- Fransen M, Neal B. Non-steroidal anti-inflammatory drugs for preventing heterotopic bone formation after hip arthroplasty. *Cochrane Database Syst Rev* 2004;3:CD001160.
- Burd TA, Lowry KJ, Anglen JO. Indomethacin compared with localized irradiation for the prevention of heterotopic ossification following surgical treatment of acetabular fractures. *J Bone Joint Surg [Am]* 2001;83-A:1783-8.
- Matta JM, Siebenrock KA. Does indomethacin reduce heterotopic bone formation after operations for acetabular fractures?: a prospective randomised study. *J Bone Joint Surg [Br]* 1997;79-B:959-63.
- McLaren AC. Prophylaxis with indomethacin for heterotopic bone after open reduction of fractures of the acetabulum. *J Bone Joint Surg [Am]* 1990;72-A:245-7.
- Kjaersgaard-Andersen P, Nafei A, Teichert G, et al. Indomethacin for prevention of heterotopic ossification: a randomized controlled study in 41 hip arthroplasties. *Acta Orthop Scand* 1993;64:639-42.
- Burd TA, Hughes MS, Anglen JO. Heterotopic ossification prophylaxis with indomethacin increases the risk of long-bone nonunion. *J Bone Joint Surg [Br]* 2003;85-B:700-5.
- Fransen M, Anderson C, Douglas J, et al. Safety and efficacy of routine postoperative ibuprofen for pain and disability related to ectopic bone formation after hip replacement surgery (HIPAID): randomized controlled trial. *BMJ* 2006;333:519.
- Pellegrini VD Jr, Konski AA, Gastel JA, Rubin P, Evarts CM. Prevention of heterotopic ossification with irradiation after total hip arthroplasty: radiation therapy with a single dose of eight hundred centigray administered to a limited field. *J Bone Joint Surg [Am]* 1992;74-A:186-200.
- Lo TC, Healy WL, Covall DJ. Heterotopic bone formation after hip surgery: prevention with single dose postoperative hip irradiation. *Radiology* 1988;168:851-4.

49. **Gregoritch SJ, Chadha M, Pelligrini VD, Rubin P, Kantorowitz DA.** Randomized trial comparing preoperative versus postoperative irradiation for prevention of heterotopic ossification following prosthetic total hip replacement: preliminary results. *Int J Radiat Oncol Biol Phys* 1994;30:55-62.
50. **Cooley LM, Goss RJ.** The effects of transplantation and x-irradiation on the repair of fractured bones. *Am J Anat* 1958;102:167-81.
51. **Craven PL, Urist MR.** Osteogenesis by radioisotope labelled cell populations in implants of bone matrix under the influence of ionizing radiation. *Clin Orthop* 1971;76:231-3.
52. **Coventry MB, Scanlon PW.** The use of radiation to discourage ectopic bone: a nine-year study in surgery about the hip. *J Bone Joint Surg [Am]* 1981;63-A:201-8.
53. **Sylvester JE, Greenberg P, Selch MT, Thomas BJ, Amstutz H.** The use of postoperative irradiation for the prevention of heterotopic bone formation after total hip replacement. *Int J Radiat Oncol Biol Phys* 1998;14:471-6.
54. **Healy WL, Lo TC, DeSimone AA, Rask B, Pfeifer BA.** Single-dose irradiation for the prevention of heterotopic ossification after total hip arthroplasty: a comparison of doses of five hundred and fifty and seven hundred centigray. *J Bone Joint Surg [Am]* 1995;77-A:590-5.
55. **Seegenschmiedt MH, Keilholz L, Martus P, et al.** Prevention of heterotopic ossification about the hip: final results of two randomized trials in 410 patients using either preoperative or postoperative radiation therapy. *Int J Radiat Oncol Biol Phys* 1997;39:161-71.
56. **Konski A.** The use of postoperative irradiation for the prevention of HO after THA with biologic fixation (porous coated) prosthesis: an animal model. *Int J Radiat Oncol Biol Phys* 1990;18:861-5.
57. **Jasty M.** Radiation-blocking shields. *Clin Orthop* 1990;257:138-45.
58. **Kim J.** Radiation induced soft tissue and bone sarcomas. *Radiology* 1978;129:501-8.
59. **Patel HYC, Silverman CL, Carrascosa L, et al.** Evaluation of scrotal and testicular dose when using radiation for heterotopic ossification prophylaxis. *Int J Radiat Oncol Biol Phys* 2005;63:340-1.
60. **Howell SJ, Shalet SM.** Spermatogenesis after cancer treatment: damage and recovery. *J Natl Cancer Inst Monogr* 2005;34:12-7.
61. **Kinsella TJ, Trivette G, Rowland J, et al.** Long-term follow-up of testicular function following radiation therapy for early-stage Hodgkin's disease. *J Clin Oncol* 1989;7:718-24.
62. **Wroblewski BM, Shelley P.** Reattachment of the greater trochanter after hip replacement. *J Bone Joint Surg [Br]* 1985;67-B:736-40.
63. **Hofmann S, Trnka HJ, Metzgeroth H, et al.** General short-term indomethacin prophylaxis to prevent heterotopic ossification in total hip arthroplasty. *Orthopedics* 1999;22:207-11.
64. **Barthel T, Baumann B, Noth U, Eulert J.** Prophylaxis of heterotopic ossification after total hip arthroplasty: a prospective randomized study comparing indomethacin and meloxicam. *Acta Orthop Scand* 2002;73:611-14.
65. **van Leeuwen WM, Deckers P, de Lange WJ.** Preoperative irradiation for prophylaxis of ectopic ossification after hip arthroplasty: a randomized study in 62 hips. *Acta Orthop Scand* 1998;69:116-18.
66. **Neal BC, Rodgers A, Clark T, et al.** A systematic survey of 13 randomized trials of non-steroidal anti-inflammatory drugs for the prevention of heterotopic bone formation after major hip surgery. *Acta Orthop Scand* 2000;71:122-8.
67. **Kolbl O, Knelles D, Barthel T, et al.** Preoperative irradiation versus the use of non-steroidal anti-inflammatory drugs for prevention of heterotopic ossification following total hip replacement: the results of a randomized trial. *Int J Radiat Oncol Biol Phys* 1998;42:397-401.
68. **Knelles D, Barthel T, Karrer A, et al.** Prevention of heterotopic ossification after total hip replacement: a prospective, randomised study using acetylsalicylic acid, indomethacin and fractional or single-dose irradiation. *J Bone Joint Surg [Br]* 1997;79-B:596-602.
69. **Kolbl O, Knelles D, Barthel T, et al.** Randomized trial comparing early postoperative irradiation vs the use of nonsteroidal antiinflammatory drugs for prevention of heterotopic ossification following prosthetic total hip replacement. *Int J Radiat Oncol Biol Phys* 1997;39:961-6.
70. **Sell S, Willms R, Jany R, et al.** The suppression of heterotopic ossifications: radiation versus NSAID therapy: a prospective study. *J Arthroplasty* 1998;13:854-9.
71. **Bremen-Kuhne R, Stock D, Franke C.** Indomethacin: short-term therapy vs. single low dosage radiation for prevention of periarthral ossifications after total hip endoprosthesis. *Z Orthop Ihre Grenzgeb* 1997;135:422-9 (in German).
72. **Kienapfel H, Koller M, Wust A, et al.** Prevention of heterotopic bone formation after total hip arthroplasty: a prospective randomised study comparing postoperative radiation therapy with indomethacin medication. *Arch Orthop Trauma Surg* 1999;119:296-302.
73. **Pakos EE, Ioannidis JP.** Radiotherapy vs. nonsteroidal anti-inflammatory drugs for the prevention of heterotopic ossification after major hip procedures: a meta-analysis of randomized trials. *Int J Radiat Oncol Biol Phys* 2004;60:888-95.
74. **Moed BR, Letournel E.** Low-dose irradiation and indomethacin prevent heterotopic ossification after acetabular fracture surgery. *J Bone Joint Surg [Br]* 1994;76-B:895-900.
75. **Pakos EE, Pitouli EJ, Tsekeris PG, et al.** Prevention of heterotopic ossification in high-risk patients with total hip arthroplasty: the experience of a combined therapeutic protocol. *Int Orthop* 2006;30:79-83.
76. **Piatek S, Westphal T, Arbter D, Winckler S.** Value of a combined ossification prophylaxis with indomethacin and radiotherapy for acetabular fractures. *Unfallchirurg* 2006;109:556-62 (in German).